

## IMAGES IN INTERVENTION

# Short-Cut Under Pressure

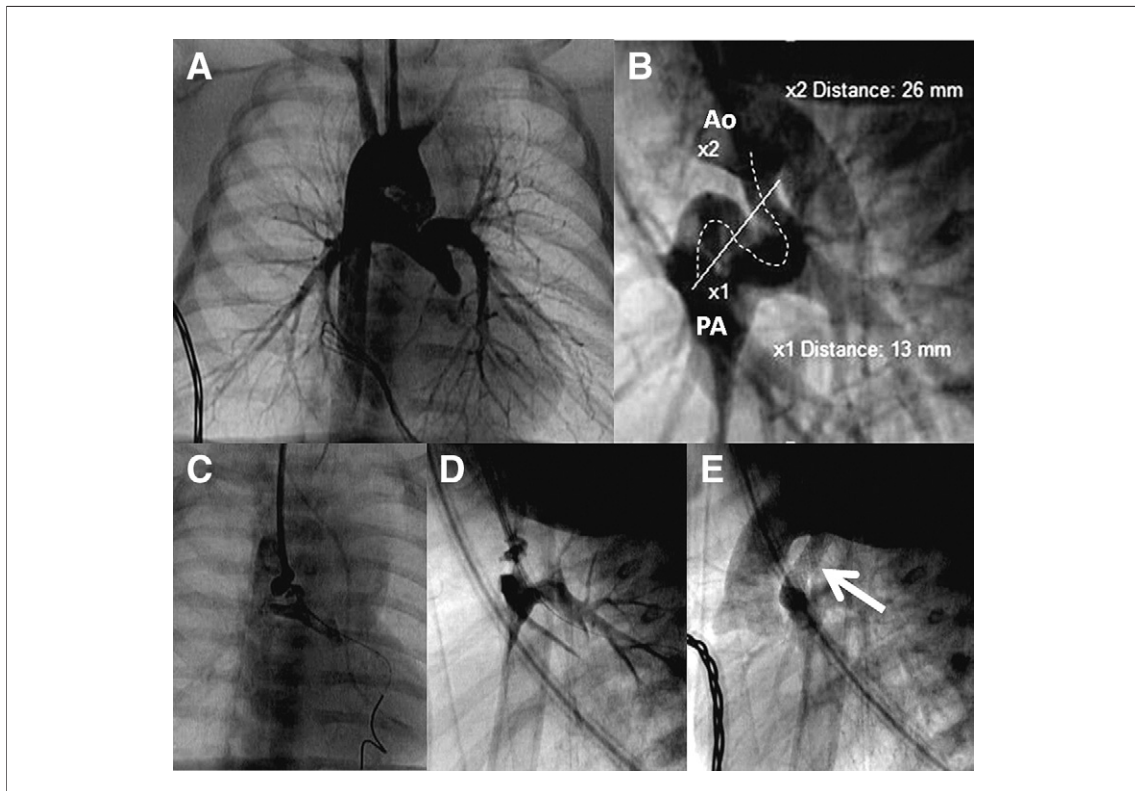
## Stenting the Tortuous Neonatal Duct Involves Induced Spasm

Mieke Roggen, MD,\* Filip Rega, MD, PhD,† Marc Gewillig, MD, PhD‡

Leuven, Belgium

A neonate (3,410 g) presented with a duct-dependent complex pulmonary atresia (double discordance, ventricular septal defect, right aortic arch).

The duct originated with an obtuse angle from the inner curvature of the aorta facing the right carotid artery (Fig. 1A, Online Video 1); it was



**Figure 1. Sequence of Stenting the Tortuous Neonatal Duct**

(A) Aortogram through the 4-F sheath from the right carotid artery. The duct originates just across the right carotid artery in a right arch. (B) Lateral view of aortogram. The duct originates from the cross of the aorta in a vertical way, followed by a very tortuous course with a cumulated angulation of 360°. The total length of the duct (dotted line) is 26 mm, the direct distance between aorta and pulmonary artery (solid line) measures only 13 mm. (C, D) After insertion of a stiff 0.014-inch coronary wire through the duct until the distal left pulmonary artery, the duct straightens and shortens, however with significant spasm and subtotal obstruction. (E) Aortogram after deployment of a 4/18-mm stent: the stented duct (arrow) now has a straight course; the stent covers the full length of the duct from the aortic lumen to the pulmonary artery. Ao = aorta; PA = pulmonary artery. See Online Videos 1, 2, 3, and 4.

From the \*Department of Pediatrics, University Hospital Leuven, Leuven, Belgium; †Department of Cardiac Surgery, University Hospital Leuven, Leuven, Belgium; and ‡Pediatric Cardiology, University Hospital Leuven, Leuven, Belgium. The authors have reported that they have no relationships relevant to the contents of this paper to disclose.

Manuscript received February 23, 2012, accepted March 1, 2012.

long and tortuous with a cumulative angulation of 360° (Fig. 1B). By cutdown, a 4-F sheath was positioned in the right carotid artery. A soft Progreat coaxial wire (Terumo, Japan) was advanced through the tortuous duct into the left pulmonary artery. The total duct length was 26 mm; however, the “direct distance” between the aorta and the pulmonary artery was only 13 mm. A 4/18-mm stent was prepared as we anticipated straightening the curve that would shorten and kink the duct with critical spasm. The 0.018-inch inner probing wire was exchanged for a more rigid coronary wire, Ironman 0.014 inch (Abbott Vascular, Santa Clara, California). The duct kinked and spasmed as expected (Figs. 1C and 1D, *Online Videos 2 and 3*); oxygen levels dropped from 81% to well below 60%.

The stent was forced through the duct. Great care was taken to cover the duct completely with little protrusion

in both aorta and pulmonary artery. After stent deployment, the saturation quickly rose to 93% (Fig. 1E, *Online Video 4*).

Three months later, the duct was restented with a 4.5/16-mm stent, followed by a Glenn shunt after 8 months on well-developed pulmonary arteries.

This case illustrates the critical steps: choose the right access to allow forcing the stent through a spastic duct, have an adequately sized stent prepared, and properly position the stent at deployment.

---

**Reprint requests and correspondence:** Dr. Marc Gewillig, UZ Leuven, Pediatric Cardiology, Leuven, Brabant B 3000, Belgium. E-mail: marc.gewillig@uzleuven.be.

---